Neuroscience Midterm
10th batch

1. Which one of the following is the most common cause of primary headache?
   A. Tension
   B. Migraine
   C. Cluster
   D. Sinus
   E. Primary brain tumor

➔ This question was appealed and A+B were considered right

2. Which one of the following is used as a biomarker to detect neural tube defects prenatally?
   A. Ceruloplasmin
   B. Beta HCG
   C. Apolipoprotein
   D. Alpha-fetoprotein
   E. Alpha-1 antitrypsin

Ans: D

3. A 40-year-old dentist complains of headaches and inability to control his walking (gait). Neurological examination revealed loss of hearing on the right side, tinnitus, vertigo and nausea, wide based ataxic gait and lurching on the right side. Which one of the following is most likely involved in this case?
   A. Medial medulla

B. Medial pons
C. Lateral medulla
D. Cerebellopontine angle
E. Lateral pons

Ans: D

4. A glove-&-stocking pattern of sensory disturbance usually develop with disease in:
   A. Spinal cord
   B. Peripheral nerves
   C. Brain stem
   D. Cerebellum
   E. Cerebrum

Ans: B

5. A 22-year-old male suffers massive trauma in a car accident. CT scan showed multiple intracerebral hemorrhages. He expired after 2 months. At autopsy, there were cystic spaces in parietal and frontal lobes. Which one of the following cells types resulted in formation of these cavities after clearing the hemorrhagic debris?
   A. Astrocytes
   B. Ependymal cells
   C. Neuron
   D. Oligodendrocytes
   E. Microglia

Ans: E

6. A 2-day old neonate was born with a large head circumference. An MRI with contrast was performed which showed obstruction of:
   A. Aqueduct of Sylvius
   B. Central canal
   C. Foramen of Luschka
   D. Fourth ventricle
   E. Interventricular foramen

Ans: A

7. PET scans can be used to measure blood flow in the cerebral cortex. What part of the cortex shows increasing blood flow when a subject is asked to think about moving her right finger?
   A. Basal ganglia
   B. Left primary motor cortex
   C. Left premotor cortex
   D. Left anterior cingulate cortex
   E. Right cerebellum

Ans: C

8. A patient was given certain general anesthetic. He did not need a ventilator. He seemed to be aware of the surroundings. The drug is most likely to be?
   A. Ketamine
   B. Propofol
   C. Etomidate
   D. Thiopental
   E. Mepivacaine

Ans: A

9. Ahmed gets lost in the desert while camping with his friends. He is rescued three days later by the Civil Defense and brought to the ER. Ahmed is dehydrated, and serum electrolytes show the sodium level has increased from a normal value of 140 mEq/L to 147 mEq/L. the resting membrane potential of a typical neuron is -80mV before dehydration. What is the most likely resting membrane potential after the dehydration, assuming no change in resting sodium conductance?
   A. -88 mV
   B. -72 mV
   C. -80 mV
   D. -99 mV
   E. -74 mV

Ans: C

10. What are the resident macrophages in the central nervous system?
   A. Microglia
   B. Astrocytes
   C. Oligodendrocytes
   D. Schwann cells

Ans: A

11. What is the effect of opioid agonists on opioid receptors on the membrane of postsynaptic neurons?
   A. Closure of K+ channels causing depolarization.
   B. Opening of K+ channel causing hyperpolarization.
   C. Opening of Ca+2 channels promote hyperpolarization.
   D. Opening of Cl- channels causing hyperpolarization.

Ans: B

12. A 38-year-old woman at 12 weeks of gestation presents to her obstetrician for prenatal care. On prenatal examination, one serum level was reduced, yet this finding was insignificant for the fetus. The level of a-fetoprotein was normal. Which of the following neural tube defects could the baby have?

    A. Spina bifida occulta
    B. Anencephaly
    C. Meningocele
    D. Myelomeningocele

Ans: A

13. What one of the following coordinates eye head movement?
    A. Rubrospinal
    B. Reticulospinal
    C. Vestibulospinal
    D. Tectospinal

Ans: D

14. A patient was given a certain opioid that causes psychosomatic symptoms and dysphoria. This drug is most likely to be?

A. Fentanyl
B. Diamorphine
C. Pentazocine
D. Buprenorphine
E. Naloxone

Ans: C

15. A patient has MS. He has diplopia with the lateral movement of either eyes. Which of the following structures is affected?
    A. Medial longitudinal fasciculus
    B. Abducent nerve
    C. Trochlear nerve
    D. Oculomotor nerve

Ans: A

16. A 55-year-old man discovered that he had pain in the neck and right arm and weakness in extending his fingers of his right hand with loss of sensation in the right thumb and middle fingers. A neurological examination further revealed a weakness of the right biceps reflex, but other neurological signs could not be detected. The most likely diagnosis of this individual is:
    A. Syringomyelia involving the cervical cord.
    B. A knife wound of the right arm completely severing nerves innervating the biceps.
    C. Prolapse of a cervical disk
    D. Poliomyelitis involving the cervical cord
    E. AIDS

Ans: C

17. What happens to the excitation threshold of polymodal fibers following the release of sensitizing agents during inflammation?
    A. Excitation threshold drops
    B. Excitation threshold remains the same
    C. Excitation threshold rises
    D. Irrelevant
    E. Adapts

Ans: A

Farhan, a fifth-year medical student, had a fracture of T2 vertebrae. He presented with bilateral loss of pain and temperature sensation with preservation of 2 touch discrimination and vibration. He had bilateral spastic paralysis below the lesion. He also had urinary incontinence.

18. What is the most likely affected artery?
    A. Anterior spinal artery
    B. Left vertebral artery
    C. Right vertebral artery
    D. Posterior vertebral artery

Ans: A

19. What is the most likely diagnosis?
    A. Posterior cord syndrome
    B. Central cord syndrome
    C. Anterior cord syndrome
    D. Brown syndrome
    E. Cauda equina syndrome

Ans: C

20. What is the mechanism behind the spastic paralysis?
    A. Loss of the inhibitory signals from UMN to LMN
    B. Loss of the excitatory signals from UMN to LMN
    C. Excitatory signals from LMN

Ans: A

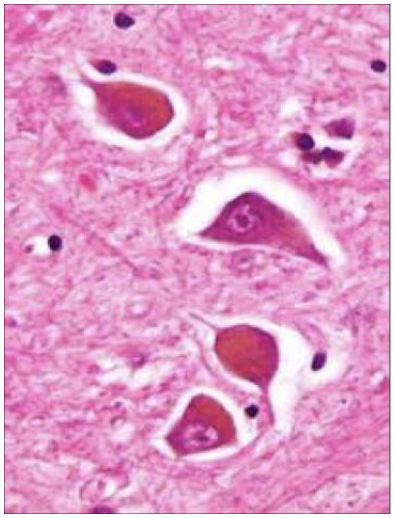

21. A 60-year-old man is brought to the emergency room in a coma. Physical examination revealed distended abdomen and laboratory studies showed elevated levels of blood ammonia. A liver biopsy demonstrated cirrhosis. Histologic examination of brain tissue from this patient would most likely show prominent changes in the nuclei of which of the following cell types?
    A. Microglia
    B. Purkinje cells
    C. Oligodendrocytes
    D. Astrocytes

Ans: D

22. A patient had a lesion in the right medial crus cerebri. What is the most likely finding?
    A. Right medial strabismus
    B. Right pupil construction

C. Right ptosis
D. Right spastic paralysis

Ans: C

23. A 67 years old woman suffered a cerebral infarction 2 weeks ago. She frequently forgets to put her left arm on her blouse. She always forgets her left side and forget to put makeup for her left side of her face. Which of the following is most likely to be affected?

A. Motor Cortex in the right hemisphere
B. Posterior Parietal cortex in the right hemisphere
C. Posterior Parietal cortex in the left hemisphere
D. Inferior temporal cortex in the right hemisphere

Ans: B

24. Sparing of which of the following will result in intact two touch discrimination and vibratory sense?

A. Dorsal white column of the spinal cord
B. Lateral white column of the spinal cord
C. Anterior white column of the spinal cord
D. Anterior gray horn cells of the spinal cord
E. Posterior gray horn cells of the spinal cord

Ans: A

25. A 10-year-old develop paralysis in his right lower limb after a viral illness. on examination, his right lower limb is flaccid, muscle mass significantly reduced as compared to the left lower limb. The knee and ankle reflexes are completely absent. Which of the following structures is affected in this case?

A. Anterior corticospinal tract
B. Lateral corticospinal tract
C. Anterior gray horn cells
D. Posterior gray horn cells
E. Lateral gray horn cells

Ans: C

26.Patient presented with deep laceration in the forearm. He lost sensation of his first 3 digits. What is the pathological process resulted in this distal presentation?

A. Demyelination of the nerve fibers
B. Liquefactive necrosis
C. Coagulation necrosis
D. Wallerian degeneration

Ans: D

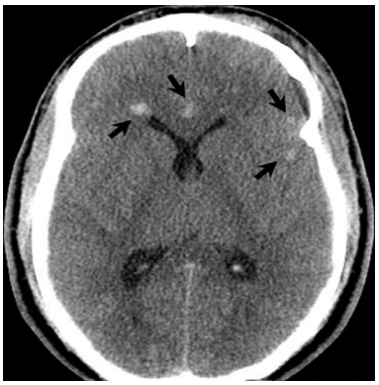

27. A patient presented to the hospital after a car accident. CT was performed immediately. What is the most likely diagnosis?

A. Subdural hemorrhage
B. Diffuse axonal injury
C. Intracerebral contusion

Ans: B

28. A boy was cooking. He touched a hot element on the oven and immediately withdrew his hand, but he burned his fingertip. Later he put water (30° C) on the burned area which was swollen and developed erythema and heat. What causes the area around the site of injury to be more sensitive to pain?

A. Acetylcholine
B. Substance P
C. Serotonin
D. Glutamate

Ans: B

29. Braille system is a raised dots system that helps blind patients to read using their fingertips. What makes using the fingertips better than the elbow to feel the letters?

A. Presence of many receptors with small receptive field.
B. Less density of the receptors on the fingertips.
C. Less representation on the sensory cortex.

Ans: A

30. A patient had a demyelinating disease. Demyelination will cause a decrease in which one of the following?

A. length constant
B. time constant
C. temporal summation

Ans: A

31. What is the level of the spinal cord which is approached during lumbar puncture in order to take a CSF sample in adults?

A. L1-L2
B. L3-L4

C. L2-L3
D. S1-S2
E. T12-L1

Ans: B

32. What is the blood supply for the posterior limb of the internal capsule?
A. Lenticulostriate arteries
B. Anterior cerebral artery
C. Posterior cerebral artery
D. Superior cerebellar artery

Ans: A

33. A patient suffers from tertiary syphilis and ataxia. Which part of the spinal cord is most likely to be affected?
A. Anterior grey horn cells
B. Lateral white column
C. Dorsal white column

Ans: C

34. What is the tone of the muscle in UMN lesion?
A. Flaccid
B. Spastic
C. Hypotonia
D. cogwheel rigidity

Ans: B

35. When a muscle is sudden lengthened. What will be the role of muscle spindles?
   A. Activating Alpha neuron
   B. Deactivating gamma
   C. Slow the response
   D. Decrease the firing

Ans: A

36. A 55-year-old patient had sudden contractions of her limbs that was associated with hearing abnormal sounds and loss of consciousness for 30 seconds which made her to collapse. She then started to have (convulsive) movements for 2 minutes. This description best matches which of the following?
   A. Simple partial
   B. Complex partial
   C. Atonic seizure
   D. Tonic-clonic

Ans: D

37. Which of the following have the largest representation in the cortex?
   A. Forearm muscles
   B. Thumb muscles
   C. Mastication muscles
   D. Trunk muscles

Ans: B

38. A patient has many nodules on the skin near the nipples. He had adrenomedullary tumor. His urine is positive for catecholamines end products, what is the gene mutation responsible for this condition?

A. NF1
B. VHL
C. P53
D. TSC

Ans: A

39.Which structure forms nerve plexuses?

A. Ventral toot
B. Dorsal root
C. Communicating rami
D. Anterior rami
E. Posterior rami

Ans: D

40. A patient presented with right facial paralysis, right medial strabismus, and left sided spastic paralysis of his body. The lesion is most likely to be located in?

A. Right pons
B. Right medulla
C. Right midbrain
D. Left pons

Ans: A

41. Stimulatory G protein coupled receptors activates which of the following secondary messengers?

A. Ca++
B. cAMP
C. IP3
D. DAG
E. Phospholipase C

Ans: B

42. What is the most common cause for intraparenchymal brain hemorrhage?
A. Diabetes
B. AV Malformation
C. Trauma
D. Hypertension

Ans: D

43. Which type of hemorrhage is accompanied with sudden excruciating type of headache?
A. Intraparenchymal hemorrhage
B. Sub-arachnoid hemorrhage
C. Epidural hemorrhage
D. Subdural hemorrhage
E. Interventricular hemorrhage

Ans: B

44. A 5-year-old boy presented with tinnitus and hearing loss, CT scan revealed a mass in the cerebellopontine angle. What is the most likely tumor presented there?
A. Medulloblastoma
B. Oligodendroglioma

C. Ganglioglioma
D. Schwannoma
E. Astrocytoma

Ans: D

45. 23-year-old Zafar received multiple gunshot injuries in the back while resisting attempted robbery. At the local hospital after initial resuscitation, a myelography was carried out which involves injection of a radio-opaqued yein subarachnoid space and subsequent imaging by X-ray. This was done to assess the extent of damage to his spinal cord since MRI facility was not available. An MRI done the next day showed hemi-section of the spinal cord at the level of the left T8 vertebra. 3 weeks later, the neurological exam of his lower limbs showed unilateral stiffness with brisk deep tendon reflexes, and positive Babinski sign. Which of the following signs on examination is indicative of a complete hemi-section?

A. Loss of pain and sensation on the right side.
B. Intact vibration and proprioception on the right side.
C. Contralateral loss of conscious proprioception below the level of the lesion.
D. Bilateral loss of temperature and pain sensations.

Ans: A

46. A CT scan reveals crescent shaped haemorrhage. What type of hemorrhage is this?

A. Epidural
B. Subdural
C. Subarachnoid
D. Intraparenchymal

Ans: B

47. Which of the following is true about Delta wave?

A. Least in amplitude and frequency
B. Its presence in awake adults indicate brain abnormality
C. Indicates brain death

Ans: B

48. Which of the following brain tumors is associated with a mutation in IDH gene?

A. Pilocytic astrocytoma
B. Oligodendroglioma II
C. Astrocytoma grade 2
D. Astrocytoma grade 3
E. Oligodendroglioma III

➔ This question was appealed and both B+C were considered right

49. A patient presented with posture impairment and ataxia, which of the following tract is most likely affect?

A. Vestibulospinal
B. Tectospinal
C. Olivospinal
D. Reticulospinal
E. Rubrospinal

Ans: A

50. A 3-year-old child developed communicating hydrocephalus and increased head circumference. What's most likely to be obstructed?

A. Interventricular foramina
B. Aqueduct of sylvius
C. Arachnoid granulation
D. Foramen of Luschka

Ans: C

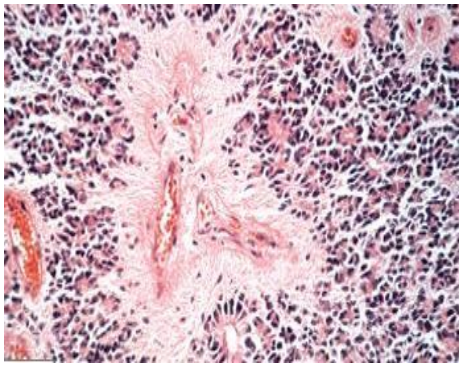

51. A 13-year-old child presents with a 3-month history of severe headaches. Vital signs and CBC are normal. Imaging studies demonstrate a mass in the fourth ventricle and hydrocephalus. The results of a CT-guided biopsy are shown in the image. What is the appropriate diagnosis for this patient's malignant neoplasm?

A. Type 4 astrocytoma
B. Ependymoma
C. Type 1 astrocytoma
D. Oligodendroglioma
E. Schwannoma

Ans: B

52. A CT scan reveals biconvex shaped hemorrhage. What type of hemorrhage is this?
A. Epidural
B. Subdural
C. Subarachnoid
D. Intraparenchymal

Ans: A

53. A patient came to the link complaining of sensory loss all the way up to the thighs. Upon examination, there was a muscle power of 3/5 on both limbs but without loss of sensory sensation on both limbs. This started in the distal lower limbs but it has now progressed all the way to the lower thighs. What sort of neuropathy is suspected in this patient?
A. Multiple sclerosis
B. Acute Inflammatory demyelinating Polyneuropathy
C. Chronic Inflammatory demyelinating polyneuropathy
D. Amyotrophic lateral sclerosis (ALS)
E. Diabetes

Ans: B

54. A lady presented with back pain. Weakness in her arms and legs. MRI was done which revealed intradural extramedullary lesion. What's the most likely diagnosis?

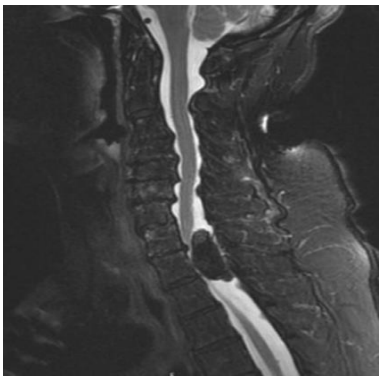

A. Meningioma
B. Neurofibroma
C. Nerve sheath tumor

Ans: A

55. A patient has lost sensation of taste from anterior 2/3 of the tongue. This sensation is received by which area in the brainstem?

A. Nucleus ambiguous
B. Nucleus tractus solitarius
C. Spinal trigeminal nucleus

Ans: B

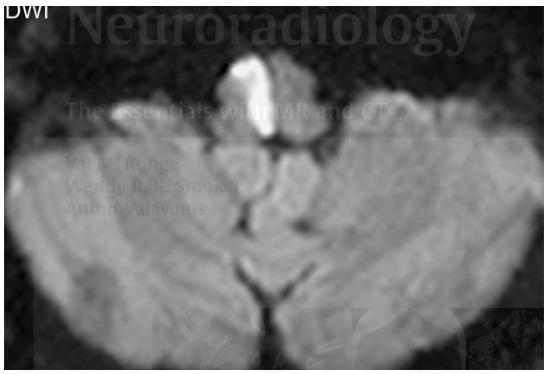

56. A patient comes to your clinic. CT was performed which revealed abnormality in this area. What's the most likely affected structure?

A. Hypoglossal nucleus
B. Red nucleus
C. Tegmentum of midbrain

Ans: A (This question was deleted because the CT was not clear. It was an infarction in the medial medulla. We had the same picture)

57. The term applied when a neuron is receives successive stimuli from the same neuron is called?

A. Temporal summation
B. Spatial summation
C. Divergence
D. Reverberatory circuit

Ans: A

58. Damage to which of the following tracts will affect unconscious proprioception?

A. Vestibulospinal
B. Spinocerebellar tract
C. Dorsal column
D. Spinothalamic

Ans: B

59. A patient presented with bilateral spastic paralysis in upper limbs, loss of pain and temperature bilaterally in the upper limbs. However, the vibration and two touch discrimination was spared. Lower limbs were not affected. What's the most likely diagnosis?

A. Central cord syndrome
B. Anterior cord syndrome
C. Poliomyelitis
D. Cauda equina syndrome

Ans: A

60. A patient presented with symptoms of spastic paralysis, hyperreflexia, weakness in parts of the limbs and flaccid paralysis This abnormality is most likely to be?

A. Motor neuron disease
B. Dorsal root ganglia disease
C. Ventral root disease

Ans: A

Collected by:
10th Batch Exam Committee
Our message to you is ..

" Educate yourself. When a question about a certain topic pops up, google it. Watch movies and documentaries. When something sparks your interest, read about it. Read read read. Study, learn, stimulate your brain. Don't just rely on the school system, educate that beautiful mind of yours .. ALWAYS remember that the mind is not a vessel to be filled but a fire to be kindled "

Good Luck :)